

Right Iliac Fossa Pain other than Appendicitis: A Pictorial Review

Adrian Goudie*

Emergency Department, Fiona Stanley Hospital, Perth, Australia

Abstract

Right iliac fossa pain is a common presentation. Although appendicitis is the most common surgical emergency, many other pathologies can have similar presentations and should be considered. This review describes the findings and shows examples of conditions other than appendicitis that should be examined for in a patient who presents with right iliac fossa pain, particularly if the appendix is not seen or seen to be normal.

Keywords: Abdominal pain, right iliac fossa, ultrasound

INTRODUCTION

Right iliac fossa pain is a common presentation to the emergency department.^[1,2] Although appendicitis is the most common surgical emergency,^[3] there are many other causes of right iliac fossa pain that must be considered when evaluating these patients [Table 1].^[1-3] Ultrasound is frequently recommended as the primary imaging modality for the investigation of acute abdominal pain, especially in young patients,^[4-6] and can often demonstrate the cause of the pain in these patients. This article will describe some of the pathologies, other than appendicitis, that can present as right iliac fossa pain, and that may be seen when scanning a patient for “query appendicitis.”

INFECTIOUS COLITIS

Infectious colitis and gastroenteritis generally present with more diarrhea and vomiting than usually occurs in appendicitis, but there can be considerable overlap in patient symptoms.^[6] Ultrasound findings consist of thickened bowel wall, which may show hyperemia. The normal bowel wall thickness is <3 mm.^[7] Focal inflammation of the adjacent bowel can occur with appendicitis, but in infectious colitis, the thickened area of the bowel extends beyond the region of the appendix, and a normal appendix may also be

seen [Figure 1 and Video 1]. Other causes of colitis (such as ulcerative colitis) may give similar appearances^[8] but can usually be distinguished clinically.

TERMINAL ILEITIS

Terminal ileitis can be due to infectious causes and Crohn's disease. Thickened bowel (>3 mm) may be seen in both causes. Crohn's disease may also show loss of the bowel wall layers, creeping fat, strictures, and other complications of inflammatory bowel disease,^[8] but ultrasound may not be able to distinguish between infectious and inflammatory bowel disease. In susceptible patients, tuberculosis can also cause terminal ileitis^[9] [Figure 2].

RIGHT-SIDED DIVERTICULITIS

In Western populations, diverticulitis is typically seen in the descending and sigmoid colon and only uncommonly occurs in the cecum or ascending colon. Right-sided diverticulitis is more common in oriental populations, where it typically occurs in younger patients and is often misdiagnosed initially as appendicitis.^[10] Ultrasound findings are similar to left-sided diverticulitis with an outpouching of the bowel

Received: 24-01-2023 Accepted: 01-02-2023 Available Online: 21-03-2023

Videos available on: www.jmuonline.org

Access this article online

Quick Response Code:



Website:
www.jmuonline.org

DOI:
10.4103/jmu.jmu_6_23

Address for correspondence:

Dr. Adrian Goudie,
Emergency Department, Fiona Stanley Hospital, 11 Robin Warren Drive,
Murdoch 6150, Australia.
E-mail: adrian.goudie@health.wa.gov.au

This is an open access journal, and articles are distributed under the terms of the Creative Commons Attribution-NonCommercial-ShareAlike 4.0 License, which allows others to remix, tweak, and build upon the work non-commercially, as long as appropriate credit is given and the new creations are licensed under the identical terms.

For reprints contact: WKHLRPMedknow_reprints@wolterskluwer.com

How to cite this article: Goudie A. Right iliac fossa pain other than appendicitis: A pictorial review. J Med Ultrasound 2023;31:8-12.

containing echogenic material, diverticular wall thickening, and surrounding echogenic fat at the point of maximal tenderness^[11] [Figure 3 and Video 2].

MECKEL’S DIVERTICULITIS

Meckel’s diverticulum occurs in approximately 2% of the population, and if it becomes inflamed, it can mimic appendicitis. Ultrasound findings are similar to other forms of diverticulitis or appendicitis (thick-walled, cystic mass with adjacent echogenic fat), but the diverticulum cannot be traced to the cecum but instead arises from the distal ileum. More frequently, Meckel’s diverticula can present with gastrointestinal bleeding (due to gastric heterotopic gastric tissue) or bowel obstruction related to intussusception or remnant bands.^[12]

INTUSSUSCEPTION

Intussusception is classically seen in young children, who may or may not be able to localize their pain when the ileum invaginates into the colon (ileocolic intussusception). It is the most common cause of small-bowel obstruction in children. Ultrasound shows a thickened, multilayered appearance of bowel within bowel, described as an “onion” or “target” sign when viewed in transverse orientation. Centrally, there will be a crescentic hyperechoic region due to invaginated mesentery [Figure 4 and Video 3].^[13,14] There is increasing recognition of short segment, brief, transient, self-resolving ileoileal intussusception without an identified lead point, which may be incidental or occur in association with many other conditions (due to hyperperistalsis, lymphoid hyperplasia, focal wall thickening, etc.). As this type of intussusception is self-resolving, it does not have the same treatment

implications as either persisting intussusception or ileocolic intussusception.^[8,15,16]

MESENTERIC ADENITIS

Multiple enlarged (>8 mm in short axis of at least one) lymph nodes may be due to presumed viral infection

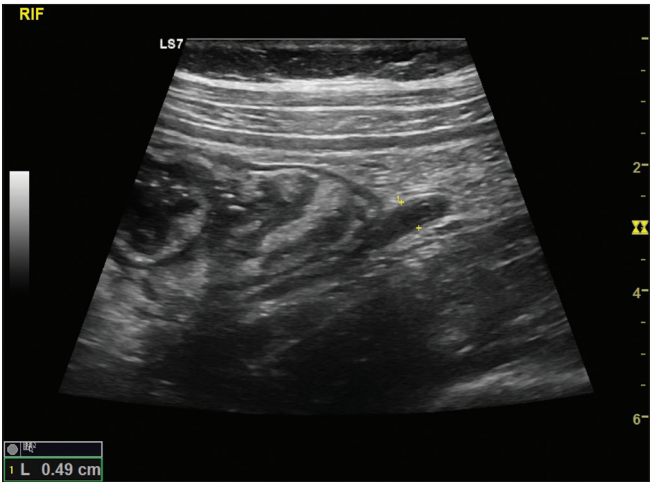


Figure 1: Infective colitis: A normal appendix is seen adjacent to thickened bowel wall (maximal thickness was 4 mm) of the cecum. Stool culture grew Campylobacter

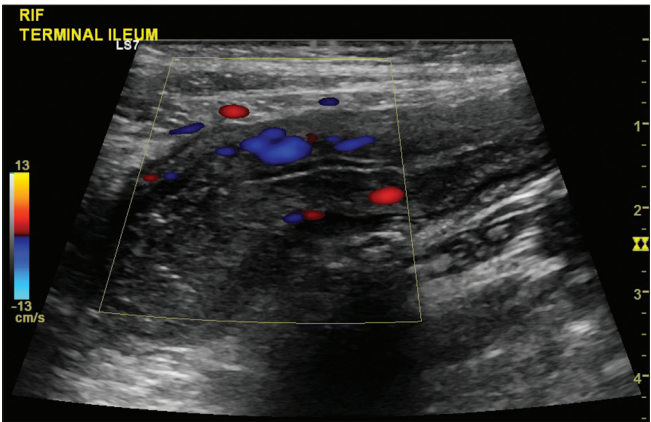


Figure 2: Crohn's Disease: Markedly thickened and hyperemic terminal ileum with a loss of the bowel wall layers was seen in a patient referred for “grumbling appendix.” Crohn's disease was confirmed on subsequent colonoscopy

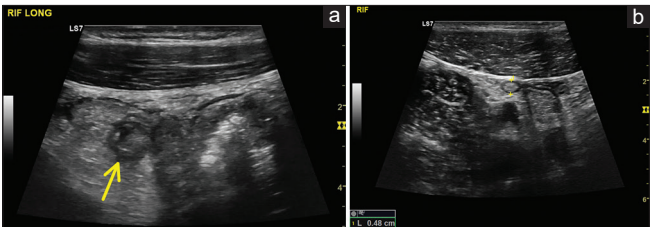


Figure 3: Right-sided diverticulitis: (a) At the point of maximal tenderness, an outpouching (arrow) was seen arising from the ascending colon with echogenic content and surrounding echogenic fat. The wall of the adjacent ascending colon was thickened. (b) The normal appendix

Table 1: Causes of right iliac fossa pain
Appendicitis
Meckel’s diverticulitis
Mesenteric adenitis
Infective colitis (typhilitis)
Terminal ileitis/Crohn’s disease
Right-sided diverticulitis
Sigmoid diverticulitis
Epiplonic appendagitis
Omental infarction
Intussusception
Renal colic/stone
Pyelonephritis
Cholecystitis
Ovarian cyst rupture
Ovarian torsion
Endometriosis
Pelvic inflammatory disease
Ectopic pregnancy
Rectus sheath hematoma
Inguinal hernia
Psoas abscess
Shingles

and are a common cause of right iliac fossa pain in children [Figure 5 and Video 4].^[17] However, reactive lymph nodes can occur in association with many conditions (including appendicitis), so careful examination to exclude other pathologies should be performed before concluding the pain is due to mesenteric adenitis.

EPILOIC APPENDAGITIS

Epiploic appendagitis is due to the infarction of an epiploic appendage, usually due to torsion or thrombosis of its feeding vessels. Ultrasound shows a tender, hyperechoic, avascular, ovoid mass surrounded by a hypoechoic rim that is typically 2–4 cm and attached to the parietal peritoneum [Figure 6].^[18] As thrombosis of the feeding vessels may be secondary to the inflammation of nearby structures, careful examination for other pathologies should be performed.

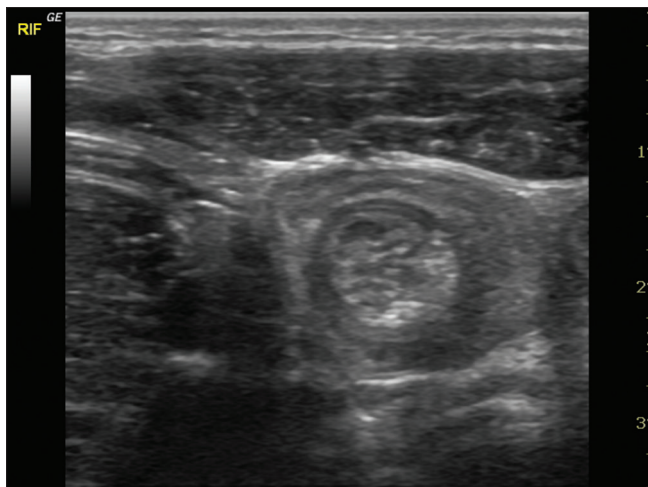


Figure 4: Intussusception: The “target” or “onion” appearance of bowel within bowel seen in intussusception

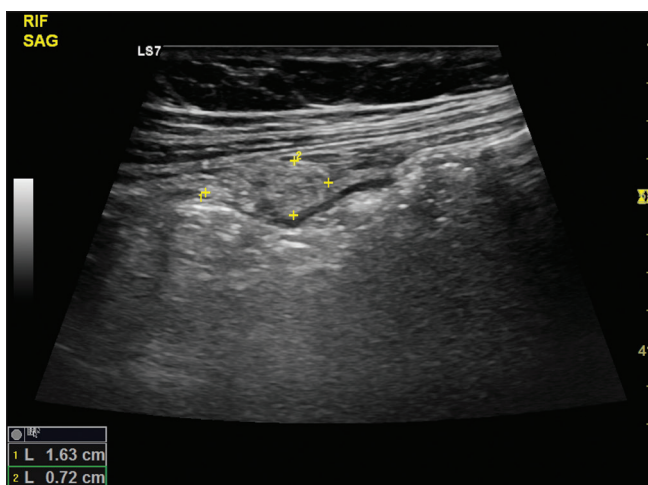


Figure 6: Epiploic Appendagitis: An ovoid, echogenic mass with a hypoechoic rim was seen adjacent to the peritoneum at the site of maximal tenderness. No other abnormality was found

RIGHT RENAL COLIC AND PYELONEPHRITIS

Although the clinical presentation of renal colic is typically different (flank pain and microscopic hematuria), a distal ureteric stone may present as right iliac fossa pain. Ultrasound generally shows hydronephrosis and an echogenic, shadowing stone may be seen in the ureter [Figure 7].^[19]

Similarly, the clinical presentation of pyelonephritis is usually evident; however, it should be remembered that appendicitis may occasionally cause leukocytes in the urine (especially if the inflamed appendix is lying adjacent to the bladder).^[3] Ultrasound in pyelonephritis is generally normal but may show either hypoechoic or hyperechoic segmental areas and an area of reduced color Doppler flow [Figure 8]. Ultrasound can also be useful to detect hydronephrosis or abscess formation.^[19]

OVARIAN PATHOLOGY

Ovarian pathologies, such as hemorrhagic cysts, cyst rupture, and torsion, may all present as right iliac fossa pain in female patients,

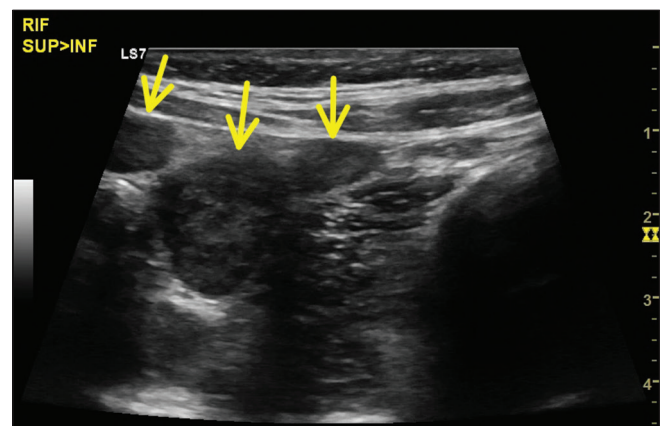


Figure 5: Mesenteric Adenitis: Multiple lymph nodes are seen in the right iliac fossa (arrows). A normal appendix was also visualized and no other abnormality seen

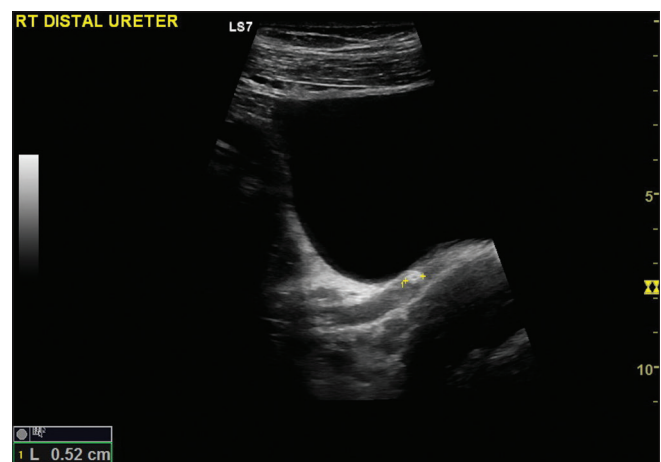


Figure 7: Renal Colic: An echogenic, shadowing mass is seen in the dilated distal ureter. Hydronephrosis of the right kidney was also present (not shown)

Goudie: RIF pain

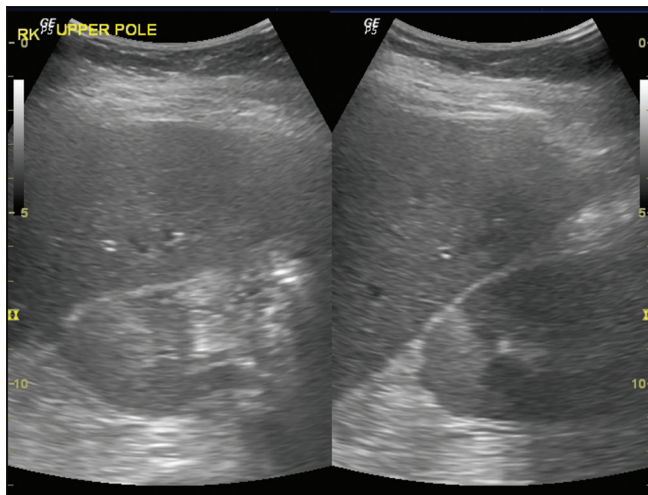


Figure 8: Pyelonephritis: The upper pole of the kidney contained a wedge-shaped echogenic region. Urine examination was consistent with pyelonephritis

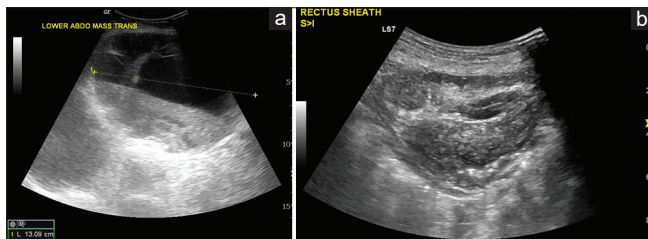


Figure 10: Rectus sheath Hematoma: Two anticoagulated patients, both showing a large hematoma in the abdominal wall. (a) A fluid–fluid level while (b) A heterogeneous echogenic mass

although usually with a more rapid onset of pain. Ovarian torsion, in particular, can be a difficult clinical and sonographic diagnosis with varied clinical presentation (vomiting is reported between 30% and 80% and pain levels can fluctuate). Sonographic features are classically an enlarged, edematous ovary with prominent follicles due to hyperechoic rims [Figure 9 and Video 5], and a focal ovarian mass (e.g., cyst). The ovary may be in an abnormal position. A “whirlpool sign” of the twisted pedicle has high specificity but poor sensitivity. It should be remembered that the presence of color Doppler flow is seen in half of (surgically proven) ovarian torsion cases, and spectral Doppler may reveal both arterial and venous flow.^[20–22]

ABDOMINAL WALL PATHOLOGY

Right-sided rectus sheath hematomas typically occur in anticoagulated patients and cause focal tenderness. They appear as lens-shaped mass in the anterior abdominal wall, contained by the rectus sheath and may be anechoic, show heterogeneous echogenicity, or a fluid–fluid level [Figure 10].^[23]

PSOAS ABSCESS

Psoas abscesses can occur from primary hematogenous seeding or secondary to spread from adjacent infection. If

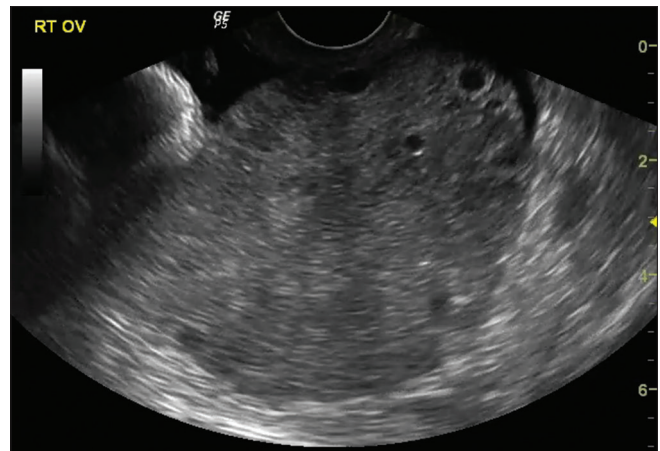


Figure 9: Ovarian torsion: An enlarged (141 mL), edematous ovary with prominent peripheral follicles is seen. No ovarian mass was seen, and color Doppler flow was present (not shown). Surgery confirmed ovarian torsion

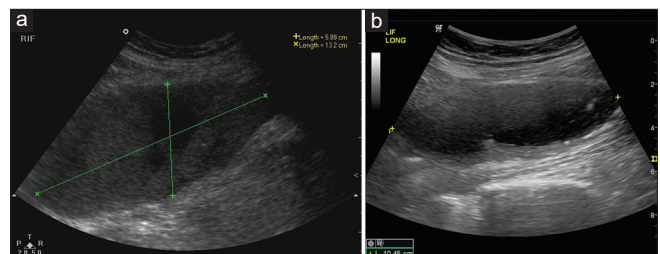


Figure 11: Psoas Abscesses: Both images show a heterogeneous collection within the psoas with a loss of the normal striated muscle pattern. (a) Is a right psoas abscess from *Staphylococcus*, (b) is a left psoas abscess due to tuberculosis

right sided, it can cause right iliac fossa pain and tenderness, classically associated with hip pain. Ultrasound demonstrates a heterogeneous mass within the psoas muscle with a loss of the normal muscle striation [Figure 11a and b].^[24]

CONCLUSION

Appendicitis is a common cause of right iliac fossa pain, but there are many other causes that must be considered. While the history and clinical examination will generally guide the differential diagnosis, there is often overlap of the findings, so ultrasound can be extremely useful in these patients. In particular, if ultrasound demonstrates a normal appendix, or the appendix is not seen, then other causes should be considered and specifically examined for.

Financial support and sponsorship

Nil.

Conflicts of interest

There are no conflicts of interest.

REFERENCES

1. Chiu DT. Abdominal pain. In: Wolfson AB, editor. *Harwood-Nuss' Clinical Practice of Emergency Medicine*. 7th ed. Philadelphia: Lippincott Williams & Wilkins; 2020.

2. Martinez JP. Abdominal pain. In: Walls RM, editor. *Rosen's Emergency Medicine: Concepts and Clinical Practice*. 10th ed. Philadelphia: Elsevier; 2023.
3. Banerjee A. Acute appendicitis. In: Peter C, Little M, Mitra B, Deasy C, editors. *Textbook of Adult Emergency Medicine*. 5th ed. Edinburgh: Elsevier; 2019.
4. Gans SL, Pols MA, Stoker J, Boermeester MA, expert steering group. Guideline for the diagnostic pathway in patients with acute abdominal pain. *Dig Surg* 2015;32:23-31.
5. Iliac Fossa Pain (Acute Right). *Diagnostic Imaging Pathways*; 2015. Available from: https://radiologycrossborders.org/diagnostic_imaging_pathways/imaging%E2%80%91pathways/gastrointestinal/acute%E2%80%91abdomen/acute%E2%80%91right%E2%80%91iliac%E2%80%91fossa%E2%80%91pelvic%E2%80%91pain. [Last accessed on 2023 Jan 20].
6. Carlberg DJ, Himelfarb NT. Acute appendicitis. In: Ron MW, editor. *Rosen's Emergency Medicine: Concepts and Clinical Practice*. 10th ed. Philadelphia: Elsevier; 2023.
7. Saevik F, Maconi F, Gilja OH. Gastrointestinal ultrasound (GIUS) – Normal findings. In: Nurnberg D, Chammas MC, Gilja OH, Spoea I, Sirli R, editors. *WFUMB Course Book*. London; 2021. Available from: http://wfumb.info/wfumb-ultrasound-book/additional-pages/html5_output/index.html. [Last accessed on 2023 Jan 20].
8. Nyland K, Gilja OH, Dietrich CF. Gastrointestinal ultrasound. In: Nurnberg D, Chammas MC, Gilja OH, Spoea I, Sirli R, editors. *WFUMB Course Book*. London; 2021. Available from: http://wfumb.info/wfumb-ultrasound-book/additional-pages/html5_output/index.html. [Last accessed on 2023 Jan 20].
9. Gurzu S, Molnar C, Contac AO, Fetyko A, Jung I. Tuberculosis terminal ileitis: A forgotten entity mimicking Crohn's disease. *World J Clin Cases* 2016;4:273-80.
10. Epifani AG, Cassini D, Cirocchi R, Accardo C, Di Candido F, Ardu M, *et al*. Right sided diverticulitis in Western countries: A review. *World J Gastrointest Surg* 2021;13:1721-35.
11. Chiu TC, Chou YH, Tiu CM, Chiou HJ, Wang HK, Lai YC, *et al*. Right-sided colonic diverticulitis: Clinical features, sonographic appearances, and management. *J Med Ultrasound* 2017;25:33-9.
12. Dames EL, Hamouda ES. Radiologic imaging in meckel diverticulum complications. *J Med Ultrasound* 2015;23:133-41.
13. del-Pozo G, Albillos JC, Tejedor D. Intussusception: US findings with pathologic correlation – The crescent-in-doughnut sign. *Radiology* 1996;199:688-92.
14. John SD, Munden DD. The pediatric gastrointestinal tract. In: Rumack CM, Levine D, editors. *Diagnostic Ultrasound*. 5th ed. Philadelphia: Elsevier; 2018. p. 1883-69.
15. Kim JH. US features of transient small bowel intussusception in pediatric patients. *Korean J Radiol* 2004;5:178-84.
16. Kim YH, Blake MA, Harisinghani MG, Archer-Arroyo K, Hahn PF, Pitman MB, *et al*. Adult intestinal intussusception: CT appearances and identification of a causative lead point. *Radiographics* 2006;26:733-44.
17. Helbling R, Conficconi E, Wytenbach M, Benetti C, Simonetti GD, Bianchetti MG, *et al*. Acute nonspecific mesenteric lymphadenitis: More than “no need for surgery”. *Biomed Res Int* 2017;2017:9784565. Doi: <https://doi.org/10.1155/2017/9784565>.
18. Dietrich CF, Hollerweger A, Dirks K, Higginson A, Serra C, Calabrese E, *et al*. EFSUMB gastrointestinal ultrasound (GIUS) task force group: Celiac sprue and other rare gastrointestinal diseases ultrasound features. *Med Ultrason* 2019;21:299-315.
19. Tublin M, Levine D, Thurston W and Wilson SR. The kidney and urinary tract. In: Rumack CM, Levine D, editors. *Diagnostic Ultrasound*. 5th ed. Philadelphia: Elsevier; 2018. p. 310-80.
20. Shadinger LL, Andreotti RF, Kurian RL. Preoperative sonographic and clinical characteristics as predictors of ovarian torsion. *J Ultrasound Med* 2008;27:7-13.
21. Vijayalakshmi K, Reddy GM, Subbiah VN, Sathiya S, Arjun B. Clinico-pathological profile of adnexal torsion cases: A retrospective analysis from a tertiary care teaching hospital. *J Clin Diagn Res* 2014;8:C04-7.
22. Yatsenko O, Vlachou PA, Glanc P. Predictive value of single or combined ultrasound signs in the diagnosis of ovarian torsion. *J Ultrasound Med* 2021;40:1163-72.
23. Hatjipetrou A, Anyfantakis D, Kastanakis M. Rectus sheath hematoma: A review of the literature. *Int J Surg* 2015;13:267-71.
24. Al-Sadhan NA, Liebmann O, Dwyer KH. Point-of-care ultrasound identification of iliopsoas abscess in emergency department: A case report. *Clin Pract Cases Emerg Med* 2020;4:404-6.